

Two-stage laparoscopic liver resection for bilateral colorectal liver metastasis

M. A. Machado · F. F. Makdissi · R. C. Surjan ·
G. T. Kappaz · N. Yamaguchi

Received: 23 March 2009 / Accepted: 30 August 2009
© Springer Science+Business Media, LLC 2010

Abstract

Background Hepatectomy may prolong the survival of colorectal cancer patients with liver metastases. Two-stage liver surgery is a valid option for the treatment of bilobar colorectal liver metastasis. This video demonstrates technical aspects of a two-stage pure laparoscopic hepatectomy for bilateral liver metastasis. To the authors' knowledge, this is the first description of a two-stage laparoscopic liver resection in the English literature.

Methods A 54-year-old man with right colon cancer and synchronous bilobar colorectal liver metastasis underwent laparoscopic right colon resection followed by oxaliplatin-based chemotherapy. The patient then was referred for surgical treatment of liver metastasis. Liver volumetry showed a small left liver remnant. Surgical planning was for a totally laparoscopic two-stage liver resection. The first stage involved laparoscopic resection of segment 3 and ligation of the right portal vein. The postoperative pathology showed high-grade liver steatosis. After 4 weeks, the left liver had regenerated, and volumetry of left liver was 43%. The second stage involved laparoscopic right hepatectomy using the intrahepatic Glissonian approach. Intrahepatic access to the main right Glissonian pedicle was achieved with two small incisions, and an endoscopic

vascular stapling device was inserted between these incisions and fired. The line of liver transection was marked following the ischemic area. Liver transection was accomplished with the Harmonic scalpel and an endoscopic stapling device. The specimen was extracted through a suprapubic incision. The falciform ligament was fixed to maintain the left liver in its original anatomic position, avoiding hepatic vein kinking and outflow syndrome.

Results The operative time was 90 min for stage 1 and 240 min for stage 2 of the procedure. The recoveries after the first and second operations were uneventful, and the patient was discharged on postoperative days 2 and 7, respectively.

Conclusion Two-stage liver resections can be performed safely using laparoscopy. The intrahepatic Glissonian approach is a useful tool for pedicle control of the right liver, especially after previous dissection of the hilar plate.

Keywords Colorectal · Laparoscopy · Liver · Metastasis · Technique · Two-stage

Electronic supplementary material The online version of this article (doi:10.1007/s00464-009-0859-7) contains supplementary material, which is available to authorized users.

M. A. Machado (✉) · F. F. Makdissi · R. C. Surjan ·
G. T. Kappaz · N. Yamaguchi
LIM-37; Department of Gastroenterology, University of São
Paulo, Rua Evangelista Rodrigues 407-05463-000, São Paulo,
Brazil
e-mail: dr@drmarcel.com.br

Hepatectomy may prolong the survival time for colorectal cancer patients with liver metastases [1]. Recent advances in laparoscopic devices and experience with advanced techniques have increased the indications for laparoscopic liver resection [2]. Two-stage liver resection is a valid option available to patients for whom a complete resection with a single hepatectomy is not possible or safe [3].

The video demonstrates technical aspects of a two-stage pure laparoscopic hepatectomy for bilateral liver metastasis. To our knowledge, this is the first description of a two-stage laparoscopic liver resection in the English literature.

Patients and methods

A 54-year-old man with right colon cancer and synchronous bilateral colorectal liver metastasis underwent laparoscopic right colon resection followed by oxaliplatin-based chemotherapy. The patient then was referred for surgical treatment of liver metastasis. Liver volumetry showed a small left liver remnant, and computed tomography (CT) scan exhibited moderate liver steatosis. The surgical decision was to perform a totally laparoscopic two-stage liver resection.

For both procedures, the patient was placed in the supine position with the surgeon standing between his legs. The number, type, and location of the trocars are described elsewhere [4]. In the first stage of the operation, laparoscopic resection of segment 3 under a hemi-Pringle maneuver [4] was followed by ligation of the right portal vein [5, 6]. Postoperative pathology confirmed high-grade liver steatosis.

Reevaluation of the patient after 4 weeks showed that the left liver had regenerated. Volumetry of the future liver remnant was 43%.

In the second stage of the operation, laparoscopic right hepatectomy was performed using the intrahepatic Glissonian approach without the Pringle maneuver or hilar dissection [7, 8]. Intrahepatic access to the main right Glissonian pedicle was achieved with two small incisions (Fig. 1). An endoscopic vascular stapling device was

inserted between these incisions, and the stapler was fired [7, 8]. The line of liver transection was marked along the liver surface following the ischemic area.

Liver transection was accomplished with the Harmonic scalpel and an endoscopic stapling device as appropriate (Ethicon Endo Surgery Industries, Cincinnati, OH, USA). The specimen was extracted in a retrieval bag through a suprapubic incision. The falciform ligament then was fixed to maintain the left liver in its original anatomic position, avoiding hepatic vein kinking [9]. The raw liver surface was checked for bleeding and bile leakage, and one round 19-Fr Blake abdominal drain (Ethicon, Inc., Cincinnati, OH, USA) was left in place.

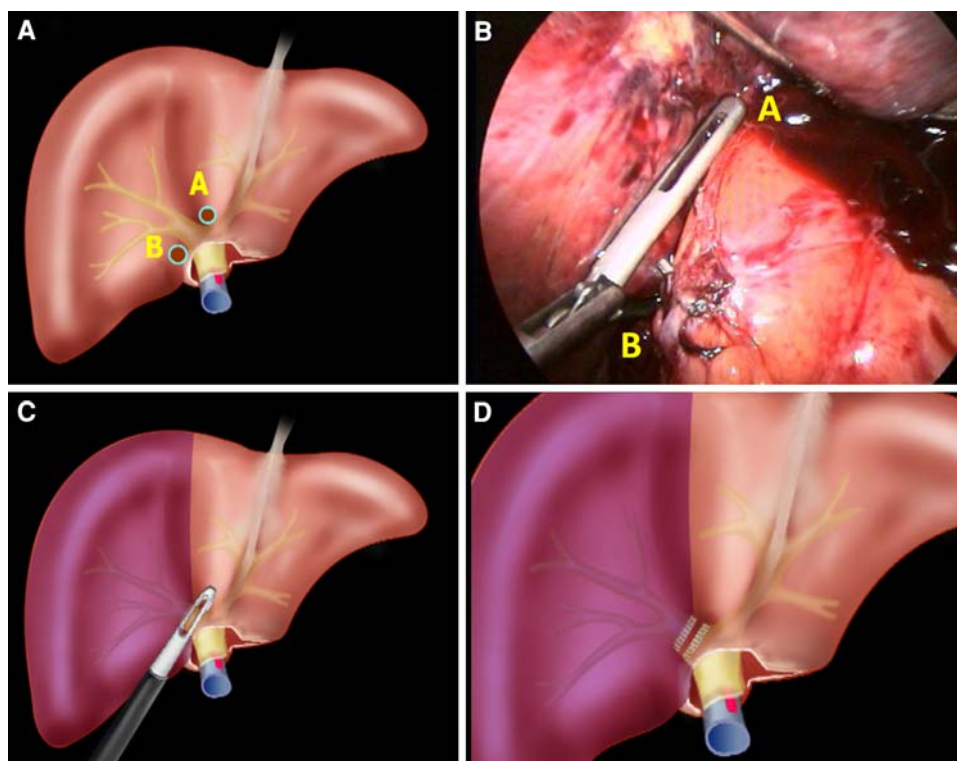
Results

The operative time was 90 min for stage 1 and 240 min for stage 2 of the procedure. The recoveries after the first and the second operations were uneventful, and the patient was discharged on postoperative days 2 and 7, respectively.

Discussion

Recently, several multidisciplinary therapies have been used to increase the resectability rate for patients with initially nonresectable colorectal liver metastasis. These

Fig. 1 Intrahepatic Glissonian technique for right hemihepatectomy. **a** Incisions (A and B) for the intrahepatic approach to the right pedicle (containing arterial, portal, and bile duct branches of segments 5–8). **b** Intraoperative photograph. A large laparoscopic vascular clamp is introduced through incisions A and B. **c** The Glissonian pedicle is temporarily occluded, and ischemic delineation of the right liver (segments 5–8) is obtained. **d** The stapler is fired, leaving three lines of suture. Inflow control of the right liver is achieved



therapies include portal vein embolization, systemic neo-adjuvant chemotherapy, and ablative techniques. However, for patients with bilateral liver metastasis, a curative resection either cannot be achieved with a single procedure or would result in a too small future liver remnant [10].

Preoperative portal vein embolization has been used to induce compensatory hypertrophy of the future liver remnant. During liver regeneration after right portal embolization, the growth rate of liver metastases seems to be more rapid than with liver parenchyma [11]. Therefore, a new strategy design has been advocated for the treatment of these patients. Metastases located in the future liver remnant should be resected in a first-stage hepatectomy. A major hepatic resection then can be performed after portal vein embolization in a second-stage hepatectomy [10]. We have used portal vein ligation during the first stage instead of portal vein embolization. This approach is feasible and safe, inducing adequate regeneration of the future liver remnant [5, 6].

We have used open two-stage liver resection as a strategy for extremely difficult cases of bilateral metastatic liver disease in 17 patients since 2004, achieving adequate compensatory hypertrophy of the future liver remnant in all but one patient. This strategy has been applied when it has been impossible or hazardous to resect all lesions in a single procedure. Due to a higher local recurrence rate, we have decreased the use of ablative techniques in favor of liver resection [12, 13]. During the second stage, we frequently have encountered hard adhesions on the hepatic hilum and on the previous raw surface of the liver. Sometimes it has been necessary to enlarge the incision to obtain better access to the liver. Conversely, laparoscopic re-hepatectomy has been greatly facilitated by the lack of adhesions, and it has been possible to use the same trocar incisions.

Modern laparoscopic devices and experience with advanced techniques have increased the indications for laparoscopic liver resection. Previous series have demonstrated the safety and feasibility of laparoscopy for minor and major liver resections [2, 7, 8]. Comparative studies have suggested that laparoscopy is associated with less bleeding, fewer complications, and a better quality of life than open liver surgery [14].

Laparoscopic right hepatectomy usually is performed with dissection of the right hepatic artery, duct, and portal vein separately, which is tedious and time consuming. We have previously described an intrahepatic Glissonian technique, which, based on small incisions following specific anatomic landmarks, allows straightforward control of the Glissonian pedicle without hilar dissection in both the open and laparoscopic procedures [7, 8].

In the reported case, the association of multiple techniques such as laparoscopic hemihepatic ischemia [4],

laparoscopic portal vein ligation [15], and an intrahepatic approach to the right Glissonian pedicle [8] allowed successful performance of a pure laparoscopic two-stage hepatectomy procedure to achieve curative resection for initially unresectable bilateral colorectal liver metastases.

Conclusion

Two-stage liver resections can be performed safely by laparoscopy. The intrahepatic Glissonian approach is a useful tool for pedicle control of the right liver, especially after previous dissection of the hilar plate.

Disclosures M. A. Machado, F. F. Makdissi, R. C. Surjan, G. T. Kappaz, and N. Yamaguchi have no conflicts of interest or financial ties to disclose.

References

1. Fong Y, Fortner J, Sun RL, Brennan MF, Blumgart LH (1999) Clinical score for predicting recurrence after hepatic resection for metastatic colorectal cancer: analysis of 1,001 consecutive cases. *Ann Surg* 230:309–318
2. Koffron AJ, Auffenberg G, Kung R, Abecassis M (2007) Evaluation of 300 minimally invasive liver resections at a single institution: less is more. *Ann Surg* 246:385–392
3. Wicherts DA, Miller R, de Haas RJ, Bitsakou G, Vibert E, Veilhan LA, Azoulay D, Bismuth H, Castaing D, Adam R (2008) Long-term results of two-stage hepatectomy for irresectable colorectal cancer liver metastases. *Ann Surg* 248:994–1005
4. Machado MA, Makdissi FF, Bacchella T, Machado MC (2005) Hemihepatic ischemia for laparoscopic liver resection. *Surg Laparosc Endosc Percutan Tech* 15:180–183
5. Kianmanesh R, Farges O, Abdalla EK, Sauvanet A, Ruszniewski P, Belghiti J (2003) Right portal vein ligation: a new planned two-step all-surgical approach for complete resection of primary gastrointestinal tumors with multiple bilateral liver metastases. *J Am Coll Surg* 197:164–170
6. Capussotti L, Muratore A, Baracchi F, Lelong B, Ferrero A, Regge D, Delpero JR (2008) Portal vein ligation as an efficient method of increasing the future liver remnant volume in the surgical treatment of colorectal metastases. *Arch Surg* 143: 978–982
7. Machado MA, Herman P, Machado MC (2003) A standardized technique for right segmental liver resections. *Arch Surg* 138: 918–920
8. Machado MA, Makdissi FF, Galvão FH, Machado MC (2008) Intrahepatic Glissonian approach for laparoscopic right segmental liver resections. *Am J Surg* 196:e38–e42
9. Ogata S, Kianmanesh R, Belghiti J (2005) Doppler assessment after right hepatectomy confirms the need to fix the remnant left liver in the anatomical position. *Br J Surg* 92:592–595
10. Jaeck D, Oussoultzoglou E, Rosso E, Greget M, Weber JC, Bachellier P (2004) A two-stage hepatectomy procedure combined with portal vein embolization to achieve curative resection for initially unresectable multiple and bilobar colorectal liver metastases. *Ann Surg* 240:1037–1049

11. Elias D, De Baere T, Roche A, Ducreux M, Leclere J, Lasser P (1999) During liver regeneration following right portal embolization the growth rate of liver metastases is more rapid than that of the liver parenchyma. *Br J Surg* 86:784–788
12. Abdalla EK, Vauthey JN, Ellis LM, Ellis V, Pollock R, Broglio KR, Hess K, Curley SA (2004) Recurrence and outcomes following hepatic resection, radiofrequency ablation, and combined resection/ablation for colorectal liver metastases. *Ann Surg* 239:818–825
13. Abdalla EK (2009) Commentary: radiofrequency ablation for colorectal liver metastases: do not blame the biology when it is the technology. *Am J Surg* 197:737–739
14. Dagher I, Di Giuro G, Dubrez J, Lainas P, Smadja C, Franco D (2009) Laparoscopic versus open right hepatectomy: a comparative study. *Am J Surg* 198:173–177
15. Ayiomamitis GD, Low JK, Alkari B, Lee SH, Ammori BJ (2009) Role of laparoscopic right portal vein ligation in planning staged or major liver resection. *J Laparoendosc Adv Surg Tech A* 19:409–413